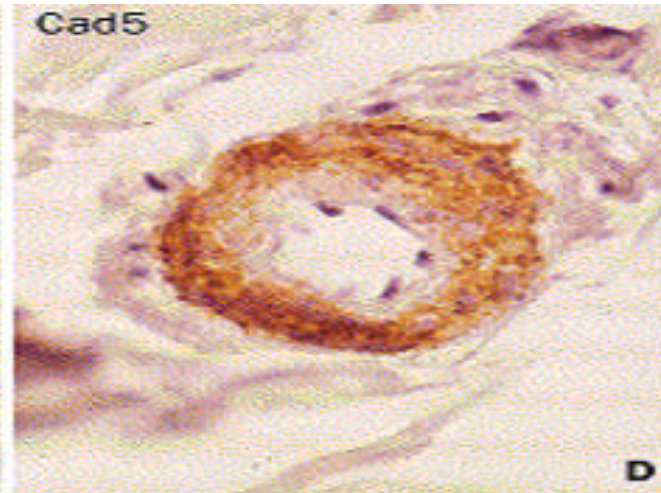
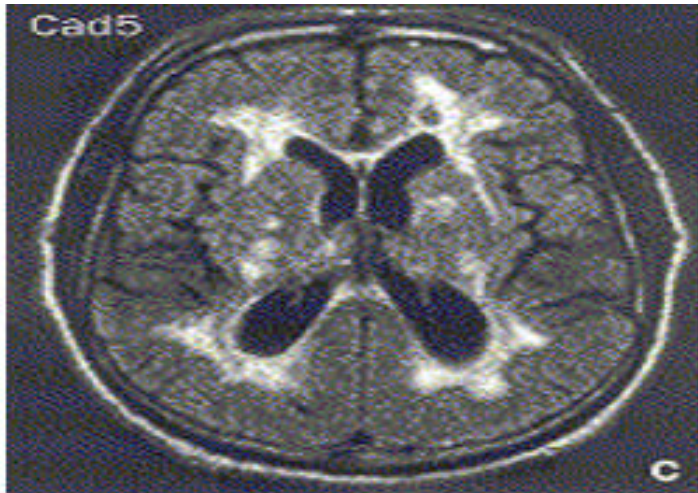


CADASIL

Skin Biopsy Results

For CADASIL Together We Have Hope Non Profit Organization (Foundation) to assist doctors in understanding CADASIL

- ***Skin biopsy:*** Granular osmiophilic deposits around
- smooth muscles and pericytes of
- small- and medium-sized arteries



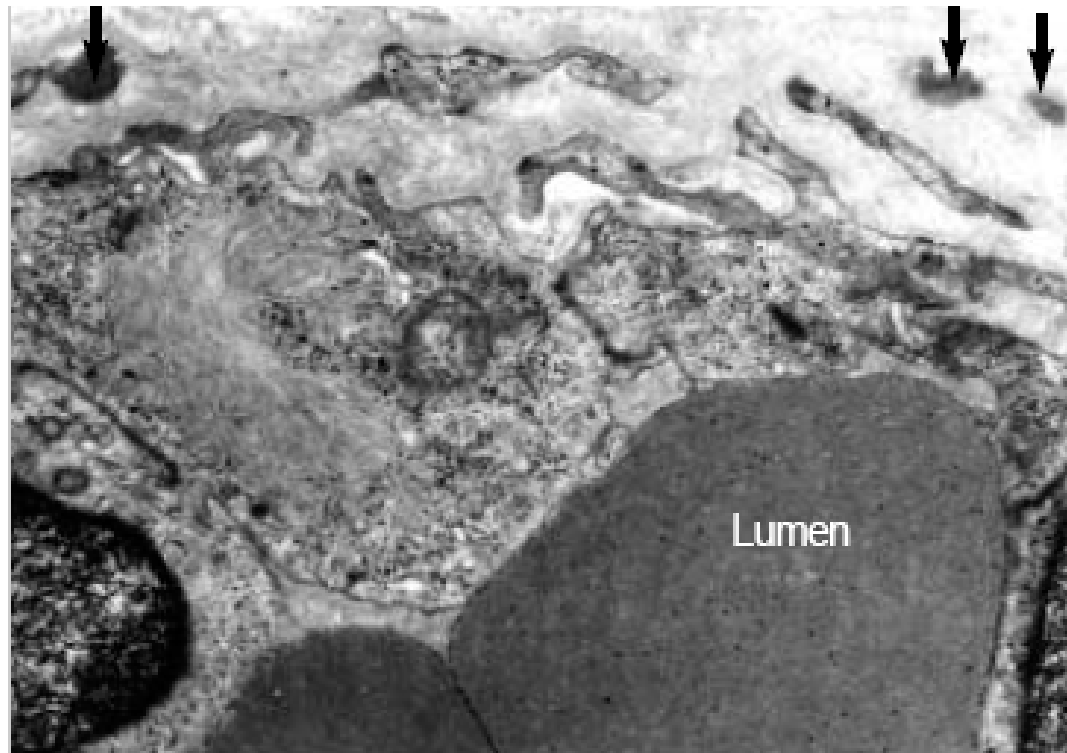


Fig. 2. Electron microscopy analysis of a skin biopsy sample showing an arteriole with fragmented vascular smooth muscle cells and a thickened basal lamina distorted by irregular deposits of granular osmiophilic material (arrow) ($\times 10,000$).

Skin Biopsy Report

- **Skin Biopsy July 1, 1997**

PATHOLOGY CONSULTATION REPORT DATED 7-1-97 ON MALE SUBJECT 41 YEARS OF AGE- ELECTRON MICROSCOPY STUDY TO HELP DIAGNOSED CADASIL

SPECIMENS RECEIVED: Skin, Left Forearm for Electron Microscopy

MICROSCOPIC: The skin specimen sections show good preservation with abundant vessels in the dermis which are selected for thin-sectioning and examination of the arterial smooth muscle cells in the vessel walls.

ELECTRON MICROSCOPY: Ultra structural study of the cutaneous vessels shows good preservation of the smooth muscle and endothelial cells without diagnostic extra cellular basement membrane-associated osmiophilic granular deposits. Multiple electron photomicrographs and additional study are without diagnostic changes. A separate grid was examined ultra structurally and found to contain diagnostic granular basement membrane- associate osmiophilic granular deposits characteristic for those associated with CADASIL. They were found intimately associated with pinocytotic vesicles in some sites.

MICROSCOPIC DIAGNOSE: SKIN OF LEFT FOREARM, PUNCH BIOPSY FOR ELECTRON

MICROSCOPY: OSMIOPHILIC GRANULAR DEPOSITS IN CUTANEOUS ARTERIAL

SMOOTH MUSCLE CELLS. (See comment).

COMMENT: The recent application of electron microscopy for the evaluation of vascular smooth muscle changes associated with CADASIL has strongly suggested that the changes in the cerebral vasculature are much in advance of those in peripheral tissues. The diagnosis is considered confirmed with the finding of granular deposits in the second portion of this tissue examined with the electron microscope. Other tissue of value in study for establishing this diagnosis includes skeletal muscle according to recent literature.

Reference: Goebel,; Characteristic Morphologic manifestation of CADASIL, In skeletal Muscle and Skin. (1997) Muscle and nerve 20: 625-627